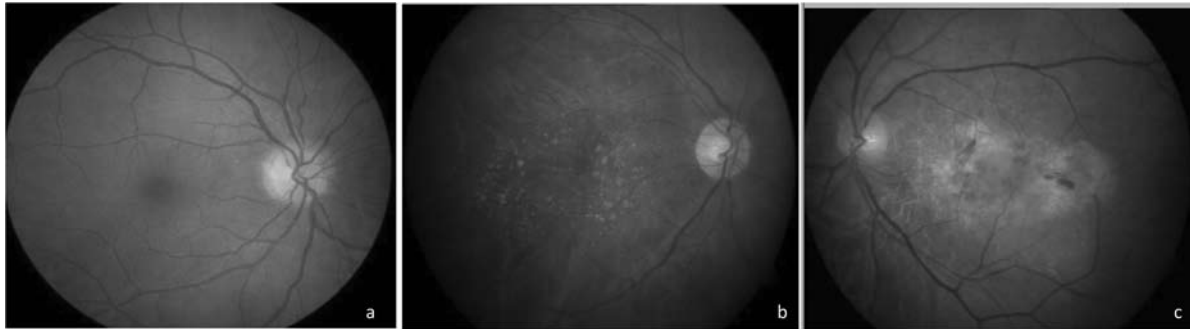
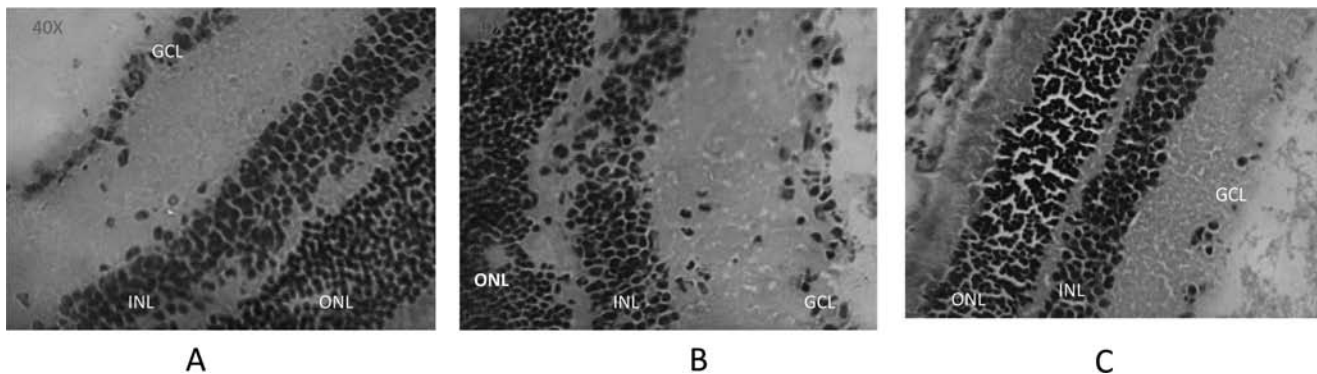


## Molecular Shots



**Fundus photographs of human eyes: a) Normal eye b) Eye with dry Age related macular degeneration (c) Eye with wet AMD Age related macular degeneration**

by *Raman Deep Singh, Neel Kamal Sharma, et al.* Department of Ophthalmology and Neuroscience Research lab, PGIMER, Chandigarh



**Histopathology of NMDA injured mouse retina, A. Control, B. 50mM NMDA, C. 100mM NMDA, > Indicates the ganglion cell disruption**

by *Neeru Jindal et al.* Neuroscience Research lab, PGIMER, Chandigarh, INDIA

doi : 10.5214/ans.0972.7531.1118213